

**MRN:** 1258469  
**Accession/Encounter No:** 123543  
**Procedure/Order ID:** 3456278  
**DOB:** 1970-01-13 **Age:** 37  
**Gender:** F  
**Height:** 67 in **Weight:** 145 lbs  
**BSA:** 1.77 m<sup>2</sup>  
**BMI:** 22.71

**Study Time:** 08:05 AM  
**Reading Group:** Juan Doe, MD  
**Referring Group:** Anytown Family Practice  
**Ordering Phys:** AAA Medical  
**Location:** East Town  
**Unit:** 5E  
**Equipment:**

**Study Quality:** Excellent  
**Indications:** Focal breast pain/tenderness  
**Diagnosis Code:** Z12.31: SCREEN MAMMOGRAM HI RISK:  
Encounter screening mammogram for malignant  
neoplasm of breast.  
**Procedure Code:** 77067: Screening mammography, bilateral (2-view study of  
each breast), including computer-aided detection (CAD) when  
performed.

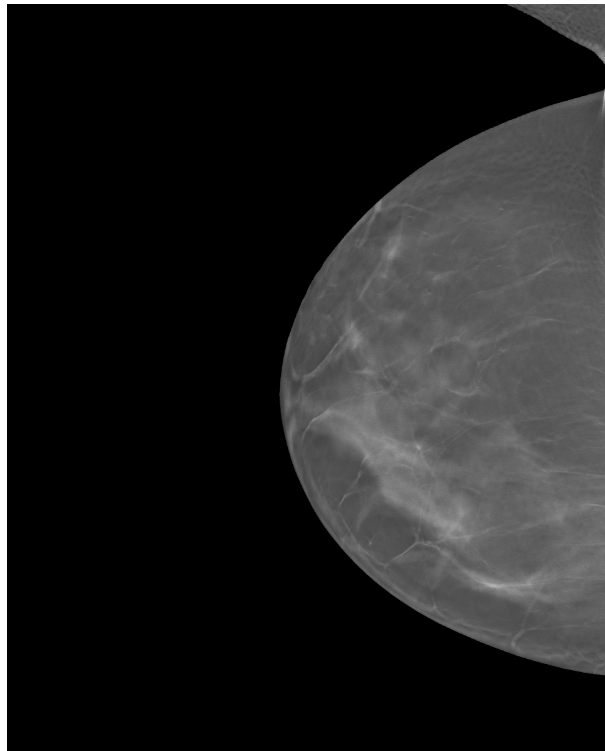
**Findings:**

The breast tissue is heterogeneously dense. This may lower the sensitivity of mammography.  
No masses, calcifications or other abnormalities are seen. No significant interval changes when compared to prior studies.

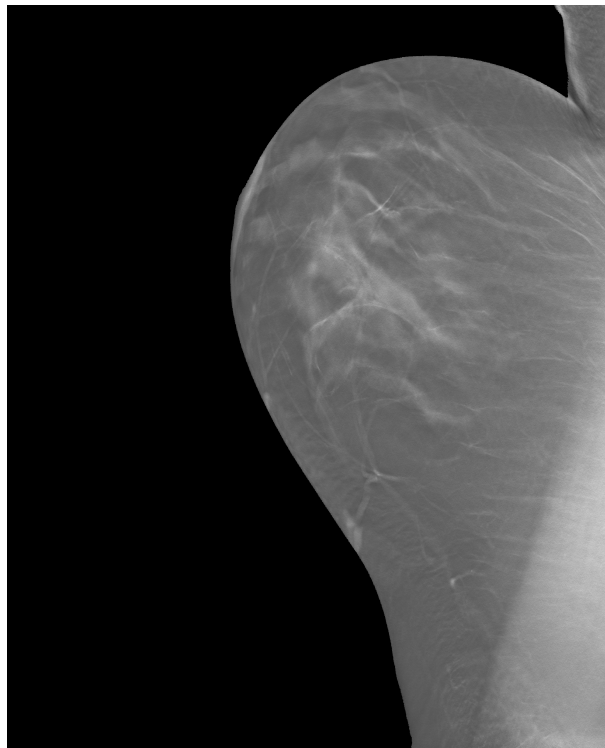
**Conclusions:**

1. Needs additional imaging and/or prior mammograms for comparison.
2. Routine screening mammography.
3. 1 month follow up recommended.

April 23, 2019 09:39 AM EDT  
CSI Admin Staff  
Electronically Signed on Studycast



comment on pictures



breast image